

Endometriosis-related infertility: ovarian endometrioma *per se* is not associated with presentation for infertility

P. Santulli^{1,2,3}, M.C. Lamau¹, L. Marcellin^{1,3}, V. Gayet¹, P. Marzouk¹, B. Borghese^{1,2}, Marie-Christine Lafay Pillet¹, and C. Chapron^{1,2,*}

¹Service de Chirurgie Gynécologie Obstétrique II et Médecine de la Reproduction, Université Paris Descartes, Sorbonne Paris Cité, Faculté de Médecine, Assistance Publique – Hôpitaux de Paris (AP-HP), Hôpital Universitaire Paris Centre (HUPC), Centre Hospitalier Universitaire (CHU) Cochin, Paris, France ²Equipe Génomique, Epigénétique et Physiopathologie de la Reproduction, Département Développement, Reproduction, Cancer, Inserm U1016, Université Paris Descartes, Sorbonne Paris Cité, Faculté de Médecine, AP-HP, HUPC, CHU Cochin, Paris, France ³Equipe Stress Oxydant, Prolifération Cellulaire et Inflammation, Département Développement, Reproduction, Cancer, Inserm U1016, Université Paris Descartes, Sorbonne Paris Cité, Faculté de Médecine, AP-HP, HUPC, CHU Cochin, Paris, France

*Correspondence address. Service de Chirurgie Gynécologie Obstétrique II et Médecine de la Reproduction, Bâtiment Port Royal, CHU Cochin, 53 avenue de l'Observatoire, 75679 Paris 14, France. Tel: +33-1-58-41-36-69; Fax: +33-1-58-41-36-68; E-mail: charles.chapron@cch.aphp.fr

Submitted on November 2, 2015; resubmitted on February 24, 2016; accepted on March 23, 2016

STUDY QUESTION: Is there an association between the endometriosis phenotype and presentation with infertility?

SUMMARY ANSWER: In a population of operated patients with histologically proven endometriosis, ovarian endometrioma (OMA) *per se* is not associated with an increased risk of presentation with infertility, while previous surgery for endometriosis was identified as a risk factor for infertility.

WHAT IS KNOWN ALREADY: The increased prevalence of endometriosis among subfertile women indicates that endometriosis impairs reproduction for reasons that are not completely understood.

STUDY DESIGN, SIZE, DURATION: This was an observational, cross-sectional study using data prospectively collected in all non-pregnant patients aged between 18 and 42 years, who were surgically explored for benign gynaecological conditions at our institution between January 2004 and March 2013. For each patient, a standardized questionnaire was completed during a face-to-face interview conducted by the surgeon during the month preceding surgery.

PARTICIPANTS/MATERIALS, SETTING, METHODS: Surgery was performed in 2208 patients, of which 2066 signed their informed consent. Of the 1059 women with a visual diagnosis of endometriosis, 870 had histologically proven endometriosis and complete treatment for their endometriotic lesions, including 307 who presented with infertility. Univariate analysis and multiple logistic regression analysis were performed to determine factors associated with infertility.

MAIN RESULTS AND THE ROLE OF CHANCE: The following variables were identified as risk factors for endometriosis-related infertility: age > 32 years (odds ratio [OR] = 1.9; 95% confidence interval [CI]: 1.4–2.4), previous surgery for endometriosis (OR = 1.9; 95% CI: 1.3–2.2), as well as peritoneal superficial endometriosis (OR = 3.1; 95% CI: 1.9–4.9); Conversely, previous pregnancy was associated with a lower rate of infertility (OR = 0.7; 95% CI: 0.6–0.9 and OR = 0.6; 95% CI: 0.4–0.9, respectively). OMA is not selected as a significant risk factor for infertility.

LIMITATIONS, REASON FOR CAUTION: The selection of our study population was based on a surgical diagnosis. We cannot exclude that infertile women with OMA associated with a diminished ovarian reserve, as assessed during their infertility work-up, were referred less frequently to surgery and might therefore be underrepresented. In addition we cannot exclude that our group of infertile women present associated other causes of infertility.

WIDER IMPLICATIONS OF THE FINDINGS: Identification of risk and preventive factors of endometriosis-related infertility can help improve clinical and surgical management of endometriosis in the setting of infertility.

STUDY FUNDING/COMPETING INTEREST(S): None.

TRIAL REGISTRATION NUMBER: None.

Keywords: endometriosis / ovarian endometrioma / female infertility / risk factor / previous history of surgery / endometrioma management

Introduction

Endometriosis, defined as the development of ectopic endometrium-like tissue outside of the uterine cavity (Sampson, 1927), is a common chronic gynaecologic disorder of still unknown origin that affects up to 10% of women of child-bearing age (Giudice, 2010). Being associated with persistent pelvic pain (Fauconnier and Chapron, 2005) and/or infertility (de Ziegler et al., 2010), endometriosis poses significant public health problem. It not only affects health, well-being and quality of life of patients, but has also great impacts on daily life, work absenteeism and health care consumption (Fourquet et al., 2010; Nnoaham et al., 2011).

The severity of endometriosis is graded according to the location, the extent and the depth of penetration of the lesions (Dubuisson and Chapron, 1994). Three different endometriosis phenotypes can be distinguished, according to whether the endometriotic lesions remain located on the peritoneal surface (superficial peritoneal endometriosis [SUP]), give rise to ovarian cysts (ovarian endometrioma [OMA]) or invade the surrounding organs beneath the peritoneum such as the bladder, the vagina, the ureter, or the rectum (deep infiltrating endometriosis [DIE]).

While there are well-established relationships between the anatomical location of endometriotic lesions and pain (Fauconnier et al., 2002; Vercellini et al., 2007; Brawn et al., 2014; Morotti et al., 2014), the link between endometriosis and infertility is less well defined. Several mechanisms have been proposed to explain endometriosis-related infertility, including inflammation, distorted pelvic anatomy, endocrine and ovulatory abnormalities, peritoneal dysfunction, and altered hormonal and cell-mediated functions in the endometrium (de Ziegler et al., 2010; Vercellini et al., 2014a). However, the relationship between the endometriosis phenotype and infertility is far from clear.

The main objective of the present study was to analyse the association between patient characteristics, endometriotic lesion location, disease stage, endometriosis phenotype and presentation for infertility in a large group of women with histologically proven endometriosis.

Materials and Methods

Study design

This was an observational, cross-sectional study using data from a prospective database, the structure of which has already been detailed and published elsewhere (Chapron et al., 2011b). Signed informed written consent was obtained from all included patients. The local Ethics Committee (Comité Consultatif de Protection des Personnes dans la Recherche Biomédicale) at our institution approved the study protocol.

Study population

The database consisted of data from all non-pregnant patients aged less than 42 years, who underwent gynaecological surgery by laparotomy or

laparoscopy from January 2004 to March 2013 at our institution. Excluded from this population were women with cancer, infectious disease and/or who refused to give their consent for participating in the study.

Indications for surgery (possibly more than one per patient) included: (i) pelvic pain defined as the presence, for at least 6 months, of dysmenorrhoea and/or intermenstrual pelvic pain and/or dyspareunia of moderate to severe intensity (Fedele et al., 2005); (ii) infertility defined as at least 12 months of unprotected intercourse not resulting in pregnancy (Marcoux et al., 1997); (iii) pelvic mass (benign ovarian cysts, uterine myomas, etc.); and (iv) others: uterine bleeding, request for tubal ligation, etc.

For the purpose of this study, patients were selected based on histological and surgical criteria: patients with no visual lesion of endometriosis at surgery as well as patients visually diagnosed with endometriosis but without histological confirmation (Chapron et al., 2010b), or patients who did not have, according to the surgeons' findings, a complete excision of endometriotic lesions (Lafay Pillet et al., 2012), were excluded from the study. The resulting study population, i.e. patients with complete surgical removal of histologically proven endometriotic lesions, was divided into two groups according to whether they presented with infertility (study group) or not (control group).

Histologically proven endometriotic lesions were classified into three phenotypes: SUP, OMA and DIE. Because these three endometriotic phenotypes can be associated, patients were classified according to their worst lesion, that is, from least to most severe: SUP, OMA and DIE (Chapron et al., 2011a). DIE was histologically defined as endometriotic lesions that infiltrate the *muscularis propria* (bladder, intestine, intrinsic ureter) after radical surgery (partial cystectomy, bowel resection, ureteral resection) (Chapron et al., 2010a). For the other locations (uterosacral ligament(s), vagina, extrinsic ureter), DIE was arbitrarily defined as endometriotic tissue infiltrating beneath the peritoneum surface deeper than 5 mm (Koninckx and Martin, 1992). DIE lesions were classified according to five locations: bladder, uterosacral ligament(s), vagina, intestine and ureter (Chapron et al., 2006). In cases of multiples DIE lesions, patients were classified according to the worst finding (least to most severe: uterosacral ligament(s), vagina, bladder, intestine and ureter) (Chapron et al., 2006). During the surgical procedure, the extent of endometriosis (stages and mean scores: total, adhesions, implants) was assessed according to the American Society for Reproductive Medicine (ASRM) classification (ASRM, 1997).

Data collection

For each patient, data were collected in face-to-face interviews conducted by the surgeon during the month preceding surgery using standardized questionnaire, as previously described (Chapron et al., 2010b). The questionnaire queried about general data (age, body mass index [BMI], family history, surgical history, obstetrical history, smoking habits, oral contraceptive pill [OCP] use), gynaecological data (characteristics about the menstrual cycle and menstruations, existence of dysmenorrhoea, existence and duration of infertility), and history of symptoms and treatment during adolescence (age at menarche, primary dysmenorrhoea and its consequences on life [e.g. absenteeism from school], prescription of OCP to treat severe primary dysmenorrhoea).

Statistical analysis

Data are presented as mean \pm standard deviation (SD) or number (percent) of subjects for continuous and categorical variables, respectively. A stepwise

multiple logistic regression was conducted to determine factors associated with infertility. First, between-group comparisons were performed using the Student's *t*-test or Pearson's χ^2 test as appropriate. Crude odds ratios (OR) with 95% confidence intervals (CI) were then estimated separately for each variable associated with infertility at a threshold of $P < 0.10$ in the previous univariate analysis. We then run a multiple logistic regression including six variables with a *P*-value less than 0.005. A stepwise ascendant selection by likelihood ratio test has been run on 4 steps selecting 4 variables with a significant adjusted OR for infertility ($P < 0.001$). After Bonferroni correction for multiple comparisons we still have an α value at 0.05 level. Statistical significance was considered at $P < 0.05$. Statistical analysis was performed using the SPSS software version 18.0.0 (SPSS Inc., Chicago, IL, USA).

Results

From January 2004 to March 2013, 2066 women underwent gynaecological surgery at our institution and gave their informed consent for

participating in the study (Fig. 1). Of these 2066 women, 1059 (51.3%) were visually diagnosed with endometriosis. The resulting patient population consisted of the 870 patients for whom endometriosis diagnosis had been histologically confirmed and complete excision of endometriotic lesions had been performed (Fig. 1). For these patients, indications for surgery were the following: painful symptoms without associated infertility (563 patients, 64.7%), pain associated to infertility (223 patients, 25.6%) and isolated infertility without pain (84 patients, 9.7%). Demographic and clinical characteristics of these 870 patients are presented in Table 1. About one-third of patients (332 cases, 38.2%) had previous surgery for endometriosis, including OMA surgery for 147 patients (16.9%). Patient's distribution according to their worst endometriotic phenotype was as follows: SUP (147 patients, 16.9%), OMA (229 patients, 26.3%), and DIE (494 patients, 56.8%). Of 494 DIE patients, 183 (37.0%) presented associated OMA (right 43, left 79 and bilateral 61). Thus, a total of 412 patients (47.4%) presented OMA. Data for

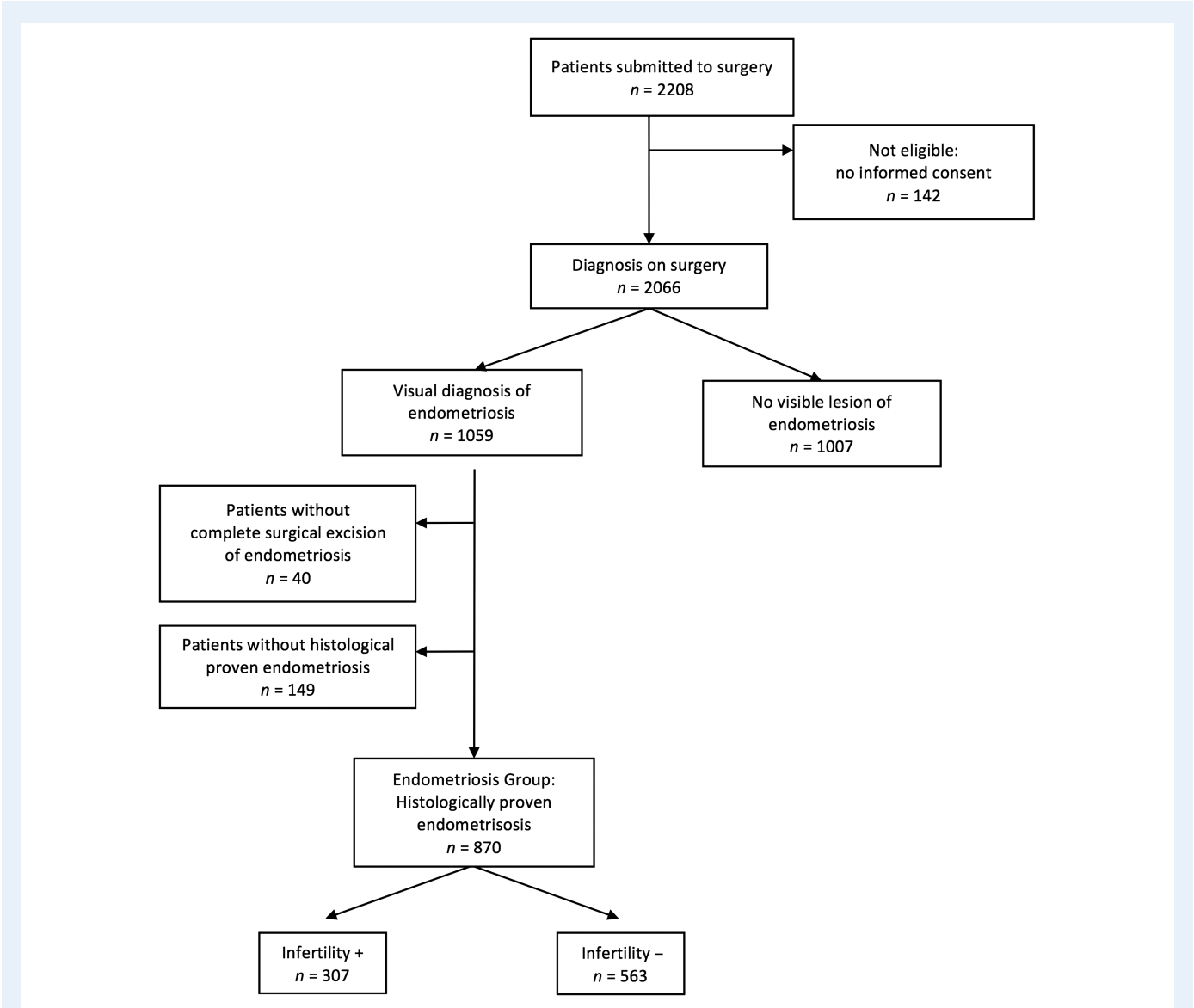


Figure 1 Patients inclusion flowchart.

Table I Baseline characteristics of endometriotic patients according to history of presentation for infertility.^a

Variable	All patients (n = 870)	Infertility+ (n = 307)	Infertility- (n = 563)	P
Age (years)	31.7 ± 5.3	32.5 ± 4.0	31.3 ± 5.9	0.001 ^e
Height (cm)	165.2 ± 6.3	165.1 ± 6.6	165.0 ± 7.1	0.849 ^e
Weight (kg)	60.1 ± 10.4	59.8 ± 10.2	60.2 ± 10.5	0.607 ^e
Body mass index (kg/m ²)	22.0 ± 3.6	21.9 ± 3.5	22.2 ± 4.3	0.378 ^e
Nulligravida	585 (67.3%)	220 (71.7%)	60 (10.7%)	<0.001 ^f
Smoking habits	390 (44.8%)	136 (44.3%)	254 (45.2%)	0.62 ^f
Familial history of endometriosis	102 (11.7%)	28 (9.1%)	74 (13.1%)	0.08 ^f
Absenteeism from school during menstruation	276 (31.7%)	103 (33.6%)	173 (30.7%)	0.39 ^f
Prescription of OCP for severe primary dysmenorrhoea	183 (21.0%)	73 (23.8%)	109 (19.4%)	0.13 ^f
Previous history of surgery for endometriosis				
Endometriosis surgery	332 (38.2%)	137 (44.6%)	195 (34.7%)	0.004 ^f
Endometrioma surgery	147 (16.9%)	62 (20.2%)	85 (15.1%)	0.063 ^f
Previous OCP use				<0.001 ^f
Never user	95 (10.9%)	30 (9.8%)	65 (11.5%)	
Ever user	576 (66.2%)	253 (82.4%)	323 (57.4%)	
Current user	199 (22.9%)	24 (7.8%)	175 (31.1%)	
Mean ASRM implants score ^b	15.0 ± 12.5	16.0 ± 13.5	14.5 ± 11.9	0.105 ^e
Mean ASRM adhesions score ^b	20.3 ± 24.3	24.2 ± 26.2	18.1 ± 22.8	0.001 ^e
Mean ASRM total score ^b	35.1 ± 31.4	40.2 ± 34.4	32.6 ± 29.7	0.001 ^e
ASRM stage ^b				<0.001 ^f
I	155 (17.8%)	59 (19.2%)	96 (17.1%)	
II	176 (20.2%)	52 (16.9%)	124 (22.0%)	
III	223 (25.6%)	59 (19.2%)	164 (29.1%)	
IV	316 (36.4%)	137 (44.6%)	179 (31.8%)	
Peritoneal superficial endometriosis (SUP)	147 (16.9%)	70 (22.8%)	77 (13.7%)	<0.001 ^f
Ovarian endometrioma isolated (OMA)	229 (26.3%)	65 (21.2%)	164 (29.1%)	
Deeply infiltrating endometriosis (DIE) ^c	494 (56.8%)	172 (56.0%)	322 (57.2%)	
With OMA	183 (37.0%)	85 (27.7%)	98 (17.4%)	
Without OMA	311 (73.0%)	87 (28.3%)	224 (39.8%)	
Mean number of DIE lesions	2.8 ± 1.9	3.2 ± 2	2.7 ± 1.8	0.004 ^e
Total number of DIE lesions				0.041 ^f
1	150 (30.1%)	43 (25.0%)	107 (33.2%)	
2	115 (23.4%)	34 (19.8%)	81 (25.1%)	
≥3	229 (46.5%)	95 (55.2%)	134 (41.7%)	
Anatomical distribution of DIE ^{c,d}				
USL	343 (69.6%)	117 (38.1%)	225 (40.0%)	0.579 ^f
Vagina	216 (43.8%)	82 (26.7%)	134 (23.8%)	0.350 ^f
Bladder	83 (16.8%)	26 (8.5%)	57 (10.1%)	0.423 ^f
Intestine	288 (58.4%)	115 (37.5%)	172 (30.6%)	0.039 ^f
Ureter	42 (8.5%)	8 (2.6%)	34 (6.0%)	0.024 ^f
Worst DIE lesion ^c				0.009 ^f
USL	115 (23.4%)	36 (21%)	79 (24.5%)	
Vagina	40 (8.1%)	8 (4.6%)	32 (10%)	
Bladder	42 (8.5%)	12 (7%)	30 (9.4%)	
Intestine	254 (51.5%)	108 (62.8%)	147 (45.6%)	
Ureter	42 (8.5%)	8 (4.6%)	34 (10.5%)	

Continued

Table I *Continued*

Variable	All patients (n = 870)	Infertility+ (n = 307)	Infertility– (n = 563)	P
Endometrioma size (cm)				
Right	4.1 ± 2.5	3.7 ± 2.6	4.1 ± 2.5	0.263 ^e
Left	4.1 ± 3.0	4.2 ± 3.1	4.4 ± 3.0	0.647 ^e

DIE, deeply infiltrating endometriosis; OCP, oral contraceptive pill; OMA, ovarian endometrioma; ASRM, American Society for Reproductive Medicine classification; USL, uterosacral ligaments.

^aData reported as mean ± standard deviation or number (%).

^bScore according to the American Society for Reproductive Medicine classification (ASRM, 1997).

^cAccording to surgical classification for DIE (Chapron *et al.*, 2006).

^dSometimes more than one for the same patient.

^eStudent's *t*-test.

^fPearson's χ^2 test.

ASRM stage, mean total, adhesions and implants scores, anatomical distribution of DIE lesions, and classification according to the worst DIE lesions are also presented in Table I.

Endometriosis was associated with presentation for infertility in 307 patients (35.3%). Demographic and clinical characteristics of endometriotic patients presenting (study group: *n* = 307; 35.3%) or not (control group: *n* = 563; 64.7%) with infertility are detailed in Table I. BMI, smoking habits, family history of endometriosis, absenteeism from school during menstruation, OCP use to treat severe primary dysmenorrhoea, and mean ASRM implants score were comparable between the two groups. Conversely, significant between-group differences were observed in age, gravidity, previous surgery for endometriosis, mean ASRM adhesions and total scores, ASRM stage, as well as extent of DIE lesions (mean and total number of DIE lesions). Compared with the control group, infertile patients presented more frequently SUP lesions (22.8% [70 patients] versus 13.7% [77 patients]; *P* < 0.001), while prevalence of DIE was similar between the two groups (56.0% [172 patients] versus 57.2% [322 patients]; *P* = ns). However, anatomical distribution of DIE lesions was more severe in the infertile group, with a significantly higher involvement of the intestine (37.5% [115 patients] versus 30.6% [172 patients]; *P* = 0.039). In addition, intestinal DIE lesion was significantly more frequently observed as the worst DIE lesion in the infertile group (62.8% [108 patients] versus 45.6% [147 patients]; *P* = 0.009).

Results of the multivariate analysis demonstrated that risk factors associated with the increased likelihood of presentation for infertility included age > 32 years, SUP endometriosis phenotype, and previous surgery for endometriosis. On the contrary, previous pregnancy (gravidity > 0) appeared as protective factors, in that it is associated with a lower rate of infertility (Table II). OMA is not selected as a significant risk factor for infertility.

Within the population of 412 OMA patients, OMA was associated with presentation for infertility in 150 patients (36.4%). Demographic and clinical characteristics of OMA patients presenting (study group: *n* = 150; 36.4%) or not (control group: *n* = 262; 63.6%) with infertility are presented in Table III. Age, BMI, gravidity, smoking habits, and OMA size were comparable between the two groups. Conversely, significant between-group differences were observed in previous surgery for endometriosis, ASRM scores and stage, as well as extent of endometriotic lesions. Compared with the control group, OMA was more frequently associated with DIE in infertile patients (56.7% [85 patients] versus 37.4% [98 patients]; *P* < 0.001). In addition, anatomical

distribution of DIE lesions was more severe in the infertile group, with significantly more intestinal location as worst DIE lesion (45.3% [68 patients] versus 26% [68 patients]; *P* < 0.001).

Discussion

This cross-sectional study, using a large hospital-based series of patients with histologically proven endometriosis, found that age, previous surgery for endometriosis, as well as SUP endometriosis phenotype, were significant risk factors for presentation for endometriosis-related infertility. Conversely, previous pregnancy was significantly associated with lower rate of infertility. After multivariate analysis OMA is not selected as a significant risk factor for presentation for infertility. For patients presenting with OMA-related infertility, OMA was more frequently associated with DIE, and particularly with the most severe form of DIE that involves intestinal lesions.

The strength of this study lays in the following points: (i) the patients were selected based on the fact that they were planned for surgery and not only according to the presence of infertility; (ii) the large number of endometriotic patients enrolled (870 women, including 307 with endometriosis-related infertility); (iii) all the patients were surgically explored and endometriosis was always histologically proven; and (iv) the analysis of the results according to endometriosis phenotypes (SUP, OMA, DIE).

Selection biases may have occurred, however, because recruitment was performed at a single centre, which is specialized in the care of severe endometriosis (DIE). This may contribute to an elevated rate of patients affected by severe forms of endometriosis and/or presenting with infertility. In addition, our study included women for whom surgery was decided, we can therefore not exclude that infertile women with OMA associated with a diminished ovarian reserve, as assessed during their infertility work-up, were referred less frequently to surgery and might therefore be underrepresented. In addition we cannot exclude the existence of potential associated other causes of infertility in our group of infertile endometriosis affected women. Finally, numerous epidemiological variables were prospectively collected using questionnaires before surgery, which may constitute potential confounding factors.

Our findings have clinical implications that are of prime importance in daily practice. The fact that, in a population of operated patients with histologically proven endometriosis, OMA *per se* is not associated with an increased risk of presentation for infertility should indeed be considered when choosing the best treatment of OMA in women desiring to

Table II Factors associated with presentation for infertility—multiple logistic regression model.

Variable	OR (95% CI)	P
Age >32 years ^a	1.9 (1.4–2.5)	<0.001
Gravidity >0	0.7 (0.6–0.9)	<0.001
Peritoneal superficial endometriosis	3.1 (1.9–4.9)	<0.001
Previous history of surgery for endometriosis	1.9 (1.3–2.2)	<0.001

CI, confidence interval; OR, odds ratio; ASRM: American Society for Reproductive Medicine classification.

^aBinary variable >32 versus ≤32 years.

conceive. The general consensus is that OMA larger than 4 cm should be surgically removed (Dunselman et al., 2014), both to reduce pain and to improve spontaneous conception rates. However, two important questions should be answered before proceeding with surgery: first, is there a relationship between OMA and infertility? and second, what are the risks associated with OMA surgical procedures on subsequent fertility?

Firstly, the impact of OMA *per se* on ovarian reserve and fertility is controversial. While it has been suggested that the presence of OMA *per se* is associated with a reduction in ovarian reserve (Maneschi et al., 1993; Uncu et al., 2013; Sanchez et al., 2014), this has been contradicted by numerous findings. In a recent study conducted in 244 women with unilateral OMA, ovulation was monitored during 6 cycles using transvaginal ultrasonography and compared between the affected and healthy ovary. Results showed that OMA does not negatively impact rate of spontaneous ovulation in the affected ovary (Maggiore et al., 2015). These results were affected neither by the laterality, number and size of OMA nor with associated DIE diagnosed using transvaginal ultrasonography. During the 6-month study period, 105 patients spontaneously conceived (43.0%; 95% CI: 36.7–49.5%) (Maggiore et al., 2015). These results are in agreement with those from Streuli et al., who demonstrated, in a large cohort of 726 patients (313 histologically proven endometriosis and 412 controls), that endometriosis and OMA *per se* (including cases with uni- or bilateral OMA) do not result in lower anti-Müllerian hormone (AMH) levels (Streuli et al., 2012). Ferrero et al. demonstrated that OMA recurrence *per se* did not have a significant effect on ovarian reserve markers (Ferrero et al., 2015). Consistently, results of our study suggest that OMA is not associated with an increased risk of infertility, infertility rate being similar in both overall endometriotic and OMA populations (35.3% (307/870) and 36.4% (50/412), respectively). As regards women undergoing assisted reproductive technologies (ART), it has been shown that, in cases of women with unilateral OMA, ovarian responsiveness to hyperstimulation was the same between the affected and intact ovary (Somigliana et al., 2015). In cases of unoperated bilateral OMA, although the responsiveness to hyperstimulation was significantly reduced, the quality of the oocytes retrieved and the chances of pregnancy were not affected (Benaglia et al., 2013). No between-group difference in *in vitro* fertilization (IVF) outcomes (clinical pregnancy rates per cycle, peak serum estradiol levels, number of oocytes retrieved, number of gonadotrophins ampoules required and number of embryos available for transfer) was observed in patients who underwent, or not, surgical treatment of OMA before IVF (Tsoumpou et al., 2009). Similarly, removing OMA before IVF did not improve the chance of pregnancy (Garcia-Velasco et al., 2004). Finally, after a surgical OMA excision,

IVF cycles outcomes were not affected by an OMA recurrence (Somigliana et al., 2011).

Secondly, numerous data have demonstrated that laparoscopic stripping of OMA damages the ovarian reserve (Benaglia et al., 2010; Raffi et al., 2012; Somigliana et al., 2012) due to inadvertent removal of healthy tissue in addition to the OMA wall (Hachisuga and Kawarabayashi, 2002; Muzii et al., 2002, 2005, 2007). This has also been confirmed by Streuli et al., who showed that, for endometriotic patients, AMH levels were decreased only in women with previous OMA surgery, independently of the presence of current OMA (Streuli et al., 2012). The negative impact of OMA surgery on the ovarian reserve is correlated to: (i) patient's age (Alborzi et al., 2014); (ii) OMA size (Roman et al., 2010; Coccia et al., 2011; Tang et al., 2013); (iii) bilateral OMA (Busacca et al., 2006; Esinler et al., 2006; Coccia et al., 2011); (iv) inexperienced surgeon (Yu et al., 2010; Muzii et al., 2011); and (v) repetitive surgery for OMA recurrence (Ferrero et al., 2015; Muzii et al., 2015). Regarding patients undergoing ART, IVF outcome was significantly impaired in women previously operated for bilateral OMA (Esinler et al., 2006; Somigliana et al., 2008). Finally live birth rate after IVF was lower in women with a diminished ovarian reserve (DOR) diagnosed after a previous OMA surgery compared with women with idiopathic DOR (Roustan et al., 2015).

All together these observations tend to indicate that OMA-related infertility, and especially the deleterious effects on ovarian reserve, may be more related to surgical treatment of OMA rather than to OMA *per se*. These are important considerations to be taken into account for the management of OMA in the setting of infertility given that: (i) there is a high risk of OMA recurrence after laparoscopic excision (Busacca et al., 1999; Koga et al., 2006; Guo, 2009); (ii) reproductive performance are significantly lower after repetitive versus primary surgery for both women seeking conception and infertile women (Vercellini et al., 2009); (iii) repetitive surgery for endometriosis recurrence does not increase the chance of pregnancy compared with ART (Pagidas et al., 1996; Cheewadhanaraks et al., 2004); (iv) endometriosis surgery before IVF does not increase the fertility results (Demiroglu et al., 2006); (v) risks of conservative management of OMA (OMA infection, follicular fluid contamination with endometrioma, pregnancy complications risk, and cancer development later in life) does not support the systematic necessity of surgery before ART, specifically in women with small OMA (Somigliana et al., 2015); and (vi) delaying attempts to conceive after surgery for endometriosis is associated with a lower pregnancy rate and a higher risk of recurrence (Somigliana et al., 2010). On the basis of all these findings, the decision to remove or not an OMA in the setting of infertility must be carefully considered.

From our point of view, laparoscopic intraperitoneal cystectomy, which is considered as the gold standard for OMA treatment (Chapron et al., 2002; Hart et al., 2005; Kennedy et al., 2005), should not be automatically performed. OMA management should be individualized and should be made on a case-by-case basis, taking into account the following parameters: patient's desire; ovarian reserve (AMH levels and antral follicle count); uni- or bilateral OMA; patient's age; existence and duration of infertility; immediate or delayed desire for pregnancy; associated infertility factors (tubal, sperm, . . .); associated DIE and/or adenomyosis; previous surgery for endometriosis, and specifically previous OMA surgery; existence and intensity of associated pelvic pain. Especially, in the case of unilateral OMA in patients without history of infertility desiring to conceive, surgery is not required

Table III Baseline characteristics of ovarian endometrioma (OMA) patients according to history of presentation for infertility.^a

Variable	Infertility+ (n = 150)	Infertility– (n = 262)	P
Age (years)	32.5 ± 3.8	31.6 ± 5.8	0.053 ^e
Height (cm)	164.6 ± 6.6	165.7 ± 8.2	0.171 ^e
Weight (kg)	60.7 ± 10.6	60.7 ± 10.9	0.946 ^e
Body mass index (kg/m ²)	22.4 ± 3.7	22.2 ± 5.0	0.703 ^e
Nulligravida	116 (77.3%)	184 (70.2%)	0.119 ^f
Smoking habits	67 (44.7%)	117 (44.7%)	0.998 ^f
Previous history of surgery for endometriosis			
Endometriosis surgery	76 (50.7%)	80 (30.7%)	<0.001 ^f
Endometrioma surgery	39 (26.0%)	55 (21.3%)	0.279 ^f
Mean ASRM implants score ^b	27.6 ± 10.1	25.0 ± 9.1	0.012 ^e
Mean ASRM adhesions score ^b	33.1 ± 25.4	24.5 ± 24.2	0.001 ^e
Mean ASRM total score ^b	60.7 ± 30.5	49.5 ± 28.9	<0.001 ^e
ASRM stage ^b			<0.001 ^f
II	0 (0%)	1 (0.4%)	
III	50 (33.3%)	138 (52.7%)	
IV	100 (66.7%)	123 (46.9%)	
Deeply infiltrating endometriosis (DIE) ^c	85 (56.7%)	98 (37.4%)	<0.001 ^f
Mean number of DIE lesions	3.8 ± 2.0	3.4 ± 1.9	0.162 ^e
Total number of DIE lesions			<0.001 ^f
1	10 (11.8%)	19 (19.4%)	
2	17 (20.0%)	21 (21.4%)	
≥3	58 (68.2%)	58 (59.2%)	
Anatomical distribution of DIE ^{c,d}			0.294 ^f
USL	57 (38.0%)	69 (26.3%)	0.013 ^f
Vagina	50 (33.3%)	48 (18.3%)	0.001 ^f
Bladder	8 (5.3%)	12 (4.6%)	0.732 ^f
Intestine	68 (45.3%)	68 (26%)	<0.001 ^f
Ureter	5 (3.3%)	14 (5.3%)	0.349 ^f
Worst DIE lesion ^c			<0.001 ^f
USL	10 (11.8%)	20 (20.4%)	
Vagina	5 (5.9%)	6 (6.1%)	
Bladder	1 (1.2%)	3 (3.1%)	
Intestine	64 (75.3%)	56 (57.1%)	
Ureter	5 (5.8%)	14 (13.3%)	
Endometrioma size (cm)			
Right	3.7 ± 2.6	4.1 ± 2.5	0.303 ^e
Left	4.2 ± 3.1	4.4 ± 3.0	0.628 ^e

DIE, deeply infiltrating endometriosis; ASRM, American Society for Reproductive Medicine classification; USL, uterosacral ligaments.

^aData reported as mean ± standard deviation or number (%).^bScore according to the American Society for Reproductive Medicine classification (ASRM, 1997).^cAccording to surgical classification for DIE (Chapron et al., 2006).^dSometimes more than one for the same patient.^eStudent's t-test.^fPearson's χ^2 test.

immediately because of the good short-term pregnancy rates despite the presence of OMA (Maggiore et al., 2015). For the other cases, three therapeutic strategies may be proposed depending on the clinical patient's situation (Fig. 2).

- (a) The first category of patients (group A according to Fig. 2) consists of women presenting with OMA-related infertility without pelvic pain. In these patients, and because of the desire to conceive, hormonal medical treatment is contraindicated. Alternative treatments

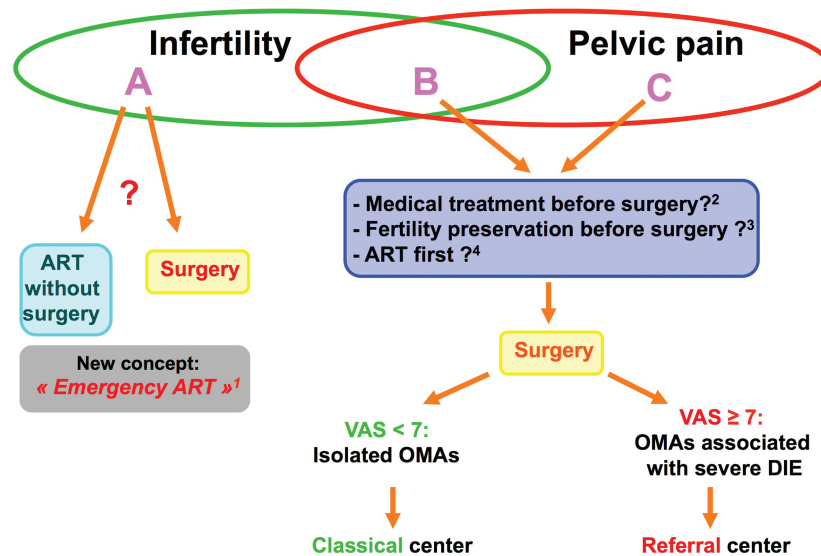


Figure 2 Ovarian endometrioma: modern management. ¹In case of altered ovarian reserve, advanced age, longlasting infertility or in case of semen characteristics or tubal status that are incompatible with natural conception, direct ART should be envisioned (de Ziegler et al., 2010). ²Antigonadotropic medical treatment may allow an expectant management in order to planned surgery in the best moment of endometriosis women life to avoid repetitive surgery (Sibiude et al., 2014). ³Given the existence of a clear risk of ovarian reserve damage after surgery, fertility preservation procedures should be proposed to patients who don't present with infertility or with no current desire to conceive (Somigliana et al., 2015). ⁴ART can be considered as a first-line option with satisfactory results in term of pregnancy (Ballester et al., 2012). ART: assisted reproductive technologies; DIE: deep infiltrating endometriosis; OMA: ovarian endometrioma; VAS: visual analogue scale.

include ART and surgery. ART should be proposed in the following cases: older patients, altered ovarian reserve, previous surgery for endometriosis, existence of associated infertility factors (male, tubal pathology,...), bilateral OMA. In patients with ovarian damage, surgery must be absolutely avoided as it may further lower the patient's ovarian reserve. In these cases, an 'emergency ART' should be envisioned, whatever the patient's age (de Ziegler et al., 2010).

- (b) The second category of patients (group C according to Fig. 2) consists of women presenting with OMA-associated pelvic pain without infertility or with no current desire to conceive. In these patients, hormonal medical treatment should be considered as the first-line therapeutic option, provided that there is no contra-indication (Ferrero et al., 2015). First-line treatment should consist of OCPs and progestogens. In case of treatment failure and/or if the treatment is not tolerated, gonadotrophin-releasing hormone (GnRH) agonists with add-back therapy may be considered as second-line therapeutic option (Descamps et al., 2014). Medical treatment should be preferred as long as it allows proper management of endometriosis, provided that a regular clinical and radiological follow-up of OMA is performed. If medical treatment fails to provide adequate pain relief, surgical treatment should be envisioned. However, it has been suggested that, in those patients with 'painful OMA', the OMA *per se* may not be the endometriotic lesion that is directly involved in the pathogenesis of pain generation. Khan et al. showed that, in women with OMA, pelvic pain was usually associated with superficial endometriosis, which is responsible of inflammatory reaction with elevated prostaglandin production and contributes to the generation of pain (Kahn et al., 2013). Similarly, Chapron et al. reported

that, in case of OMA, severe pelvic pain was significantly associated with DIE (Chapron et al., 2012). While surgical treatment of SUP is quite easy to perform, it is not the case for DIE, where complete removal of all the lesions is required for effective pain management. Given the fact that OMA was shown to be a marker for greater severity for DIE (Redwine, 1999; Chapron et al., 2009), 'painful OMA' must be considered as 'synonymous of severe DIE' with multifocal lesions and intestinal/and or ureteral involvement (Chapron et al., 2009). Surgical management of such cases requires both a thorough preoperative radiological assessment with comprehensive cartography of DIE lesions as well as a multidisciplinary operative team (involving gynaecologist, intestinal and urologist surgeons) in a reference centre dedicated to the treatment of severe endometriosis (Sibiude et al., 2014). Of note, persistence of endometriotic lesions due to an incomplete initial surgical procedure currently leads to many misleading diagnosis of endometriosis recurrence (Sibiude et al., 2014). The worst approach, for patients with 'painful OMA', would consist of a surgical excision of OMA without removal of associated DIE lesions, as it would expose the patient to the risk of iterative surgery, and thus to a cumulative risk of decrease in ovarian reserve, without providing pain relief. Furthermore, given the potentially deleterious effect of surgery on subsequent fertility, fertility preservation procedures should be proposed to patients who don't present with infertility or with no current desire to conceive (Garcia-Velasco et al., 2013; Somigliana et al., 2015).

- (c) Lastly, the third category of patients (group B according to Fig. 2) consists of women presenting with OMA-related infertility and pelvic pain. In these patients, therapeutic options include ART and

surgery. ART should be preferred in the same situations than those described for the first category of patients (group A). In the other cases, surgery should be performed as described for the second category of patients (group C). For patients who refuse surgical treatment, and/or who are not too painful, and/or who give priority to their desire to conceive, ART could be considered as a first-line option with satisfactory results in term of pregnancy (Ballester *et al.*, 2012). This therapeutic strategy may be of particular interest for patients with adenomyosis associated with endometriosis (Kunz *et al.*, 2005; Naftalin *et al.*, 2012). Adenomyosis can cause uterine bleeding (Naftalin *et al.*, 2014) and pelvic pain (Lazzeri *et al.*, 2014), and constitutes an important factor of infertility (Kunz *et al.*, 2005; Vercellini *et al.*, 2014b). In these patients, an uterine conservative DIE surgery (i.e. a surgical excision of endometriosis without hysterectomy due to the desire to conceive) would expose the patient to a high-risk and complicated surgical procedure without guaranteeing satisfactory improvement of pain and/or menorrhagia (Parker *et al.*, 2006; Ferrero *et al.*, 2009; Lazzeri *et al.*, 2014). Administration of post-ART hormonal medical treatment would allow scheduling of a single surgical intervention to perform complete removal of all the lesions (OMA, DIE and associated adenomyosis).

Overall, the objectives of these proposed strategies are: (i) first, to avoid unnecessary surgical procedures, and especially those contributing to damage ovarian reserve; and (ii) second to perform 'the endometriosis surgery' at the appropriate time. Ideally, patients should undergo surgical treatment only once in their 'endometriosis life'. In particular, use of hormonal medical treatment in patients with no immediate desire to conceive (with or without infertility) allows delaying the surgical intervention at the best time. Similarly, the place of ART in the treatment sequence should be carefully considered. Currently, ART is too often proposed at the end of the 'infertility story' after several surgical procedures, especially for OMA management. A main objective for the future would be to identify those patients for whom there are benefits to perform ART first, before the surgery.

In conclusion, our study demonstrates, in a population of operated patients with histologically proven endometriosis, that OMA *per se* has no negative impact on fertility. This has to be taken into account in daily clinical practice for the management of OMA in the setting of infertility. The general consensus considering that operative laparoscopy with OMA cyst excision represents automatically the first-line treatment needs to be revisited.

Acknowledgements

We warmly thank surgeons from our department for their expert assistance with data collection. We also thankfully acknowledge Nathalie Girma for unabatedly managing the patients' database.

Authors' roles

C.C. is the coordinator of the project. C.C. and P.S. conceived and designed the study. M.C.L., L.M., V.G., P.M., B.B., P.S. and C.C. contributed to data collection and/or performed surgical procedures. M.C.L., P.S. and C.C. analysed and interpreted the data. M.-C.L.P. performed expert statistical review. All authors contributed to the writing of the

manuscript. P.S. and C.C. revised critically the final version of the manuscript. All authors approved the final submitted version of the manuscript.

Funding

No grant supported the study.

Conflict of interest

None declared.

References

- Alborzi S, Keramati P, Younesi M, Samsami A, Dadras N. The impact of laparoscopic cystectomy on ovarian reserve in patients with unilateral and bilateral endometriomas. *Fertil Steril* 2014;**101**:427–434.
- ASRM. Revised American Society for Reproductive Medicine classification of endometriosis: 1996. *Fertil Steril* 1997;**67**:817–821.
- Ballester M, d'Argent EM, Morcel K, Belaisch-Allart J, Nisolle M, Daraï E. Cumulative pregnancy rate after ICSI-IVF in patients with colorectal endometriosis: results of a multicentre study. *Hum Reprod* 2012;**27**:1043–1049.
- Benaglia L, Somigliana E, Vighi V, Ragni G, Vercellini P, Fedele L. Rate of severe ovarian damage following surgery for endometriomas. *Hum Reprod* 2010;**25**:678–682.
- Benaglia L, Bermejo A, Somigliana E, Faulisi S, Ragni G, Fedele L, Garcia-Velasco JA. In vitro fertilization outcome in women with unoperated bilateral endometriomas. *Fertil Steril* 2013;**99**:1714–1719.
- Brawn J, Morotti M, Zondervan KT, Becker CM, Vincent K. Central changes associated with chronic pelvic pain and endometriosis. *Hum Reprod Update* 2014;**20**:737–747.
- Busacca M, Marana R, Caruana P, Candiani M, Muzii L, Calia C, Bianchi S. Recurrence of ovarian endometrioma after laparoscopic excision. *Am J Obstet Gynecol* 1999;**180**:519–523.
- Busacca M, Riparini J, Somigliana E, Oggioni G, Izzo S, Vignali M, Candiani M. Postsurgical ovarian failure after laparoscopic excision of bilateral endometriomas. *Am J Obstet Gynecol* 2006;**195**:421–425.
- Chapron C, Vercellini P, Barakat H, Vieira M, Dubuisson JB. Management of ovarian endometriomas. *Hum Reprod Update* 2002;**8**:6–7.
- Chapron C, Chopin N, Borghese B, Foulot H, Dousset B, Vacher-Lavenu MC, Vieira M, Hasan W, Bricou A. Deeply infiltrating endometriosis: pathogenetic implications of the anatomical distribution. *Hum Reprod* 2006;**21**:1839–1845.
- Chapron C, Pietin-Vialle C, Borghese B, Davy C, Foulot H, Chopin N. Associated ovarian endometrioma is a marker for greater severity of deeply infiltrating endometriosis. *Fertil Steril* 2009;**92**:453–457.
- Chapron C, Bourret A, Chopin N, Dousset B, Leconte M, Amsellem-Ouazana D, de Ziegler D, Borghese B. Surgery for bladder endometriosis: long-term results and concomitant management of associated posterior deep lesions. *Hum Reprod* 2010a;**25**:884–889.
- Chapron C, Souza C, de Ziegler D, Lafay-Pillet MC, Ngo C, Bijaoui G, Goffinet F, Borghese B. Smoking habits of 411 women with histologically proven endometriosis and 567 unaffected women. *Fertil Steril* 2010b;**94**:2353–2355.
- Chapron C, Lafay-Pillet MC, Monceau E, Borghese B, Ngô C, Souza C, de Ziegler D. Questioning patients about their adolescent history can identify markers associated with deep infiltrating endometriosis. *Fertil Steril* 2011a;**95**:877–881.

- Chapron C, Souza C, Borghese B, Lafay-Pillet MC, Santulli P, Bijaoui G, Goffinet F, de Ziegler D. Oral contraceptives and endometriosis: the past use of oral contraceptives for treating severe primary dysmenorrhea is associated with endometriosis, especially deep infiltrating endometriosis. *Hum Reprod* 2011b;**26**:2028–2035.
- Chapron C, Santulli P, de Ziegler D, Noel JC, Anaf V, Streuli I, Foulot H, Souza C, Borghese B. Ovarian endometrioma: severe pelvic pain is associated with deeply infiltrating endometriosis. *Hum Reprod* 2012;**27**:702–711.
- Cheewadhanaraks S, Peeyananjarassri K, Dhanaworavibul K, Liabsuetrakul T. Positive predictive value of clinical diagnosis of endometriosis. *J Med Assoc Thai* 2004;**87**:740–744.
- Coccia ME, Rizzello F, Mariani G, Bulletti C, Palagiano A, Scarselli G. Ovarian surgery for bilateral endometriomas influences age at menopause. *Hum Reprod* 2011;**26**:3000–3007.
- Demirol A, Guven S, Baykal C, Gurgan T. Effect of endometrioma cystectomy on IVF outcome: a prospective randomized study. *Reprod Biomed Online* 2006;**12**:639–643.
- Descamps P, Andreeva E, Leng J, Salehpour S, Chapron C. The place of gonadotropin-releasing hormone agonists in the management of endometriosis. *J Endometr Pelvic Pain Disord* 2014;**6**:1–11.
- de Ziegler D, Borghese B, Chapron C. Endometriosis and infertility: pathophysiology and management. *Lancet* 2010;**376**:730–738.
- Dubuisson JB, Chapron C. Classification of endometriosis. The need for modification. *Hum Reprod* 1994;**9**:2214–2216.
- Dunselman G, Vermeulen N, Becker C, Calhaz-Jorge C, D'Hooghe T, De Bie B, Heikinheimo O, Horne AW, Kiesel L, Nap A et al.; ESHRE guideline: management of women with endometriosis. *Hum Reprod* 2014;**29**:400–412.
- Esinler I, Bozdogan G, Aybar F, Bayar U, Yarali H. Outcome of in vitro fertilization/intracytoplasmic sperm injection after laparoscopic cystectomy for endometriomas. *Fertil Steril* 2006;**85**:1730–1735.
- Fauconnier A, Chapron C. Endometriosis and pelvic pain: epidemiological evidence of the relationship and implications. *Hum Reprod Update* 2005;**11**:595–606.
- Fauconnier A, Chapron C, Dubuisson JB, Vieira M, Dousset B, Breart G. Relation between pain symptoms and the anatomic location of deep infiltrating endometriosis. *Fertil Steril* 2002;**78**:719–726.
- Fedele L, Bianchi S, Zanonato G, Bergamini V, Berlanda N, Carmignani L. Long-term follow-up after conservative surgery for bladder endometriosis. *Fertil Steril* 2005;**83**:1729–1733.
- Ferrero S, Camerini G, Menada MV, Biscaldi E, Ragni N, Remorgida V. Uterine adenomyosis in persistence of dysmenorrhea after surgical excision of pelvic endometriosis and colorectal resection. *J Reprod Med* 2009;**54**:366–372.
- Ferrero S, Scala C, Racca A, Calanni L, Remorgida V, Venturini PL, Leone Roberti Maggiore U. Second surgery for recurrent unilateral endometriomas and impact on ovarian reserve: a case-control study. *Fertil Steril* 2015;**103**:1236–1243.
- Fourquet J, Gao X, Zavala D, Orengo JC, Abac S, Ruiz A, Laboy J, Flores I. Patients' report on how endometriosis affects health, work, and daily life. *Fertil Steril* 2010;**93**:2424–2428.
- Garcia-Velasco JA, Mahutte NG, Corona J, Zuniga V, Gilés J, Arici A, Pellicer A. Removal of endometriomas before in vitro fertilization does not improve fertility outcomes: a matched, case-control study. *Fertil Steril* 2004;**81**:1194–1197.
- Garcia-Velasco JA, Domingo J, Cobo A, Martinez M, Carmona L, Pellicer A. A five years' experience using oocyte vitrification to preserve fertility for medical and nonmedical indications. *Fertil Steril* 2013;**99**:1994–1999.
- Giudice LC. Clinical practice. Endometriosis. *N Engl J Med* 2010;**362**:2389–2398.
- Guo SW. Recurrence of endometriosis and its control. *Hum Reprod Update* 2009;**15**:441–461.
- Hachisuga T, Kawarabayashi T. Histopathological analysis of laparoscopically treated ovarian endometriotic cysts with special reference to loss of follicles. *Hum Reprod* 2002;**17**:432–435.
- Hart R, Hickey M, Maouris P, Buckett W, Garry R. Excisional surgery versus ablative surgery for ovarian endometriomata: a Cochrane Review. *Hum Reprod* 2005;**20**:3000–3007.
- Kahn KN, Kitajima M, Fujishita A, Hiraki K, Matsumoto A, Nakashima M, Masuzaki H. Pelvic pain in women with ovarian endometrioma is mostly associated with coexisting peritoneal lesions. *Hum Reprod* 2013;**28**:109–118.
- Kennedy S, Bergqvist A, Chapron C, D'Hooghe T, Dunselman G, Greb R, Hummelshoj L, Prentice A, Saridogan E; ESHRE Special Interest Group for Endometriosis and Endometrium Guideline Development Group. ESHRE guideline for the diagnosis and treatment of endometriosis. *Hum Reprod* 2005;**20**:2698–2704.
- Koga K, Takemura Y, Osuga Y, Yoshino O, Hirota Y, Hirata T, Morimoto C, Harada M, Yano T, Taketani Y. Recurrence of ovarian endometrioma after laparoscopic excision. *Hum Reprod* 2006;**21**:2171–2174.
- Koninckx PR, Martin DC. Deep endometriosis: a consequence of infiltration or retraction or possibly adenomyosis externa? *Fertil Steril* 1992;**58**:924–928.
- Kunz G, Beil D, Huppert P, Noe M, Kissler S, Leyendecker G. Adenomyosis in endometriosis—prevalence and impact on fertility. Evidence from magnetic resonance imaging. *Hum Reprod* 2005;**20**:2309–2316.
- Lafay Pillet MC, Schneider A, Borghese B, Santulli P, Souza C, Streuli I, de Ziegler D, Chapron C. Deep infiltrating endometriosis is associated with markedly lower body mass index: a 476 case-control study. *Hum Reprod* 2012;**27**:265–272.
- Lazzeri L, di Giovanni A, Exacoustos C, Tosti C, Pinzauti S, Malzoni M, Petraglia F, Zupi E. Preoperative and postoperative clinical and transvaginal ultrasound findings of adenomyosis in patients with deep infiltrating endometriosis. *Reprod Sci* 2014;**21**:1027–1033.
- Maggiore ULR, Scala C, Venturini PL, Remorgida V, Ferrero S. Endometriotic ovarian cysts do not negatively affect the rate of spontaneous ovulation. *Hum Reprod* 2015;**30**:299–307.
- Maneschi F, Marasa L, Incandela S, Mazzaresse M, Zupi E. Ovarian cortex surrounding benign neoplasms: a histologic study. *Am J Obstet Gynecol* 1993;**169**:388–393.
- Marcoux S, Maheux R, Bérubé S. Laparoscopic surgery in infertile women with minimal or mild endometriosis. Canadian Collaborative Group on Endometriosis. *N Engl J Med* 1997;**337**:217–222.
- Morotti M, Vincent K, Brawn J, Zondervan KT, Becker CM. Peripheral changes in endometriosis-associated pain. *Hum Reprod Update* 2014;**20**:717–736.
- Muzii L, Bianchi A, Crocè C, Mancini N, Panici PB. Laparoscopic excision of ovarian cysts: is the stripping technique a tissue-sparing procedure? *Fertil Steril* 2002;**77**:609–614.
- Muzii L, Bellati F, Bianchi A, Palaia I, Mancini N, Zullo MA, Angioli R, Panici PB. Laparoscopic stripping of endometriomas: a randomized trial on different surgical techniques. Part II: pathological results. *Hum Reprod* 2005;**20**:1987–1992.
- Muzii L, Bianchi A, Bellati F, Cristì E, Pernice M, Zullo MA, Angioli R, Panici PB. Histologic analysis of endometriomas: what the surgeon needs to know. *Fertil Steril* 2007;**87**:362–366.
- Muzii L, Marana R, Angioli R, Bianchi A, Cucinella G, Vignali M, Benedetti Panici P, Busacca M. Histologic analysis of specimens from laparoscopic endometrioma excision performed by different surgeons: does the surgeon matter? *Fertil Steril* 2011;**95**:2116–2119.
- Muzii L, Achilli C, Lecce F, Bianchi A, Franceschetti S, Marchetti C, Perniola G, Panici BP. Second surgery for recurrent endometriomas is more harmful to healthy ovarian tissue and ovarian reserve than first surgery. *Fertil Steril* 2015;**103**:738–743.

- Naftalin J, Hoo W, Pateman K, Mavrellos D, Holland T, Jurkovic D. How common is adenomyosis? A prospective study of prevalence using transvaginal ultrasound in a gynaecologic clinic. *Hum Reprod* 2012;**27**:3432–3439.
- Naftalin J, Hoo W, Pateman K, Mavrellos D, Foo X, Jurkovic D. Is adenomyosis associated with menorrhagia. *Hum Reprod* 2014;**29**:473–479.
- Nnoaham KE, Hummelshoj L, Webster P, d'Hooghe T, de Cicco Nardone F, de Cicco Nardone C, Jenkinson C, Kennedy SH, Zondervan KT, World Endometriosis Research Foundation Global Study of Women's Health consortium. Impact of endometriosis on quality of life and work productivity: a multicenter study across ten countries. *Fertil Steril* 2011;**96**:366–373.e8.
- Pagidas K, Falcone T, Hemmings R, Miron P. Comparison of reoperation for moderate (stage III) and severe (stage IV) endometriosis-related infertility with in vitro fertilization-embryo transfer. *Fertil Steril* 1996;**65**:791–795.
- Parker JD, Leondires M, Sinaï N, Premkumar A, Nieman LK, Stratton P. Persistence of dysmenorrhea and nonmenstrual pain after optimal endometriosis surgery may indicate adenomyosis. *Fertil Steril* 2006;**86**:711–715.
- Raffi F, Metwally M, Amer S. The impact of excision of ovarian endometrioma on ovarian reserve: a systematic review and meta-analysis. *J Clin Endocrinol Metab* 2012;**97**:3146–3154.
- Redwine DB. Ovarian endometriosis: a marker for more extensive pelvic and intestinal disease. *Fertil Steril* 1999;**72**:310–315.
- Roman H, Tarta O, Pura I, Opris I, Bourdel N, Marpeau L, Sabourin JC. Direct proportional relationship between endometrioma size and ovarian parenchyma inadvertently removed during cystectomy, and its implication on the management of enlarged endometriomas. *Hum Reprod* 2010;**25**:1428–1432.
- Roustan A, Perrin J, Debals-Gonthier M, Paulmyer-Lacroix O, Agostini A, Courbiere B. Surgical diminished ovarian reserve after endometrioma cystectomy versus idiopathic DOR: comparison of in vitro fertilization outcome. *Hum Reprod* 2015;**30**:840–847.
- Sampson JA. Peritoneal endometriosis due to the menstrual dissemination of endometrial tissue into the peritoneal cavity. *Am J Obstet Gynecol* 1927;**14**:93–94.
- Sanchez AM, Vigano P, Somigliana E, Panina-Bordignon P, Vercellini P, Candiani M. The distinguishing cellular and molecular features of the endometriotic ovarian cyst: from pathophysiology to the potential endometrioma-mediated damage to the ovary. *Hum Reprod Update* 2014;**20**:217–230.
- Sibiude J, Santulli P, MArceLLin L, Borghese B, Dousset B, Chapron C. Association of history of surgery for endometriosis with severity of deeply infiltrating endometriosis. *Obstet Gynecol* 2014;**124**:709–717.
- Somigliana E, Arnoldi M, Benaglia L, Iemmello R, Nicolosi AE, Ragni G. IVF-ICSI outcome in women operated on for bilateral endometriomas. *Hum Reprod* 2008;**23**:1526–1530.
- Somigliana E, Vercellini P, Daguati R, Giambattista E, Benaglia L, Fedele L. Effect of delaying post-operative conception after conservative surgery for endometriosis. *Reprod Biomed Online* 2010;**20**:410–415.
- Somigliana E, Benaglia L, Vercellini P, Paffoni A, Ragni G, Fedele L. Recurrent endometrioma and ovarian reserve: biological connection or surgical paradox? *Am J Obstet Gynecol* 2011;**204**:529.e1–529.e5.
- Somigliana E, Berlanda N, Benaglia L, Vigano P, Vercellini P, Fedele L. Surgical excision of endometriomas and ovarian reserve: a systematic review on serum antimüllerian hormone levels modifications. *Fertil Steril* 2012;**98**:1531–1538.
- Somigliana E, Benaglia L, Paffoni A, Busnelli A, Vigano P, Vercellini P. Risks of conservative management in women with ovarian endometriomas undergoing IVF. *Hum Reprod Update* 2015;**21**:486–499.
- Streuli I, de Ziegler D, Gayet V, Santulli P, Bijaoui G, de Mouzon J, Chapron C. In women with endometriosis anti-Müllerian hormone levels are decreased only in those with previous endometrioma surgery. *Hum Reprod* 2012;**27**:3294–3303.
- Tang Y, Chen SL, Chen X, He YX, Ye DS, Guo W, Zheng HY, Yang XH. Ovarian damage after laparoscopic endometrioma excision might be related to the size of cyst. *Fertil Steril* 2013;**100**:464–469.
- Tsoumpou I, Kyrgiou M, Gelbaya TA, Nardo LG. The effect of surgical treatment for endometrioma on in vitro fertilization outcomes: a systematic review and meta-analysis. *Fertil Steril* 2009;**92**:75–87.
- Uncu G, Kasapoglu I, Ozerkan K, Seyhan A, Oral Yilmaztepe A, Ata B. Prospective assessment of the impact of endometriomas and their removal on ovarian reserve and determinants of the rate of decline in ovarian reserve. *Hum Reprod* 2013;**28**:2140–2145.
- Vercellini P, Fedele L, Aimi G, Pietropaolo G, Consonni D, Crosignani PG. Association between endometriosis stage, lesion type, patient characteristics and severity of pelvic pain symptoms: a multivariate analysis of over 1000 patients. *Hum Reprod* 2007;**22**:266–271.
- Vercellini P, Somigliana E, Daguati R, Barbara G, Abbiati A, Fedele L. The second time around: reproductive performance after repetitive versus primary surgery for endometriosis. *Fertil Steril* 2009;**92**:1253–1255.
- Vercellini P, Vigano P, Somigliana E, Fedele L. Endometriosis: pathogenesis and treatment. *Nat Rev Endocrinol* 2014a;**10**:261–275.
- Vercellini P, Consonni D, Dridi D, Bracco B, Frattaruolo MP, Somigliana E. Uterine adenomyosis and in vitro fertilization outcome: a systematic review and meta-analysis. *Hum Reprod* 2014b;**29**:964–977.
- Yu HT, Huang HY, Soong YK, Lee CL, Chao A, Wang CJ. Laparoscopic ovarian cystectomy of endometriomas: surgeons' experience may affect ovarian reserve and live-born rate in infertile patients with in vitro fertilization-intracytoplasmic sperm injection. *Eur J Obstet Gynecol Reprod Biol* 2010;**152**:172–175.